

Topical Metronidazole Maintains Remissions of Rosacea

Mark V. Dahl, MD; H. Irving Katz, MD; Gerald G. Krueger, MD; Larry E. Millikan, MD; Richard B. Odom, MD; Frank Parker, MD; John E. Wolf, Jr, MD; Raza Aly, PhD; Charlene Bayles, BS; Brenda Reusser, BA; Melissa Weidner, RN; Edward Coleman, MS; Robert Patrignelli, MD; Michael R. Tuley, PhD; Michael O. Baker, BS; James H. Herndon, Jr, MD; Janusz M. Czernielewski, MD

Background: Rosacea is a chronic skin disease that requires long-term therapy. Oral antibiotics and topical metronidazole successfully treat rosacea. Because long-term use of systemic antibiotics carries risks for systemic complications and adverse reactions, topical treatments are preferred.

Objective: To determine if the use of topical metronidazole gel (Metrogel) could prevent relapse of moderate to severe rosacea.

Design: A combination of oral tetracycline and topical metronidazole gel was used to treat 113 subjects with rosacea (open portion of the study). Successfully treated subjects (n = 88) entered a randomized, double-blind, placebo-controlled study applying either 0.75% topical metronidazole gel (active agent) or topical metronidazole vehicle gel (placebo) twice daily (blinded portion of the study).

Setting: Subjects were enrolled at 6 separate sites in large cities at sites associated with major medical centers.

Subjects: One hundred thirteen subjects with at least 6 inflammatory papules and pustules, moderate to severe facial erythema, and telangiectasia entered the open phase of the study. Eighty-eight subjects responded to treatment with systemic tetracycline and topical metronidazole gel as measured by at least a 70% reduction in the number of inflammatory lesions. These subjects were randomized to receive 1 of 2 treatments: either 0.75% metronidazole gel or placebo gel.

Interventions: Subjects were evaluated monthly for up to 6 months to determine relapse rates.

Main Outcome Measures: Inflammatory papules and pustules were counted at each visit. Relapse was determined by the appearance of a clinically significant increase in the number of papules and pustules. Prominence of telangiectases and dryness (roughness and scaling) were also observed.

Results: In the open phase, treatment with tetracycline and metronidazole gel eliminated all papules and pustules in 67 subjects (59%). The faces of 104 subjects (92%) displayed fewer papules and pustules after treatment, and 82 subjects (73%) exhibited less erythema. In the randomized double-blind phase, the use of topical metronidazole significantly prolonged the disease-free interval and minimized recurrence compared with subjects treated with the vehicle. Eighteen (42%) of 43 subjects applying the vehicle experienced relapse, compared with 9 (23%) of 39 subjects applying metronidazole gel ($P < .05$). The metronidazole group had fewer papules and/or pustules after 6 months of treatment ($P < .01$). Relapse of erythema also occurred less often in subjects treated with metronidazole (74% vs 55%).

Conclusion: In a majority of subjects studied, continued treatment with metronidazole gel alone maintains remission of moderate to severe rosacea induced by treatment with oral tetracycline and topical metronidazole gel.

Arch Dermatol. 1998;134:679-683

The affiliations of the authors appear in the acknowledgment section at the end of the article.

ROSACEA IS A chronic dermatologic disease characterized by recurrent episodes of flushing, edema, and facial redness, complicated by papules, pustules, telangiectasia, and tissue fibrosis. The papules and pustules of rosacea mimic papules and pustules seen in acne vulgaris. Rosacea usually begins between the ages of 30 and 50 years, but can begin much earlier and coexist with ordinary acne vulgaris. Women are more likely to be affected than men.^{1,2}

Fortunately, rosacea and its acne-form components (papules and pustules) can be effectively treated in most patients. Papules and pustules are reduced or eliminated by treatment with oral antibiotics such as tetracycline. However, treatment with systemic antibiotics may cause adverse effects such as gastrointestinal intolerance, photosensitivity, and candidal vaginitis and produce worry about effects from long-term oral antibiotic use. Therefore, a need exists for topical agents to control

SUBJECTS AND METHODS

One hundred thirteen subjects with moderate to severe rosacea were enrolled in a multicenter, 4-month open-label, 6-month double-blind, vehicle-controlled study to determine the effectiveness of topical metronidazole gel as sole maintenance therapy following successful treatment with systemic tetracycline. Subjects were required to have at least 6 inflammatory lesions (papules and/or pustules), moderate to severe erythema, and telangiectasia.

Papules and pustules were counted and scores combined. Erythema was graded on a 4-point scale as follows: 0, no perceptible erythema; 1, mild—slight erythema either with restricted central involvement or generalized over the whole face; 2, moderate—pronounced erythema either with restricted central involvement or generalized over the whole face; and 3, severe—severe erythema or purple-red hue either with restricted central involvement or generalized over the whole face. Telangiectasia was graded on a 4-point scale as follows: 0, absent; 1, mild—fine vessels less than 0.2 mm in diameter covering less than 10% of the face; 2, moderate—several fine vessels and/or a few large vessels more than 0.2 mm in diameter covering between 10% and 30% of the face; and 3, many fine vessels and/or large vessels covering more than 30% of the face. Relative dryness was graded on a 7-point scale.

Prior to initiation of the study, each subject was informed about the purpose of the study and its risks and benefits and signed informed consent. In the open portion of the study, all subjects were treated initially with 250 mg of systemic tetracycline hydrochloride 4 times daily and topical metronidazole gel twice daily either until papules and pustules ceased or for 12 weeks, whichever came first. At that time the tetracycline dosage was lowered to 250 mg twice daily for 2 weeks, then 250 mg daily for 2 weeks, and

then treatment with tetracycline was stopped. Those subjects without papules and/or pustules or those with significant clinical improvement ($>70\%$ reduction in lesions) were randomized into 2 treatment groups (blinded second phase of the study). Half of the subjects applied 0.75% topical metronidazole gel twice daily, and the other half applied the vehicle gel twice daily. Subjects were followed up monthly for up to 6 months to determine the relapse rate for the 2 treatment groups. According to the protocol, subjects who experienced relapse were withdrawn from the study. Relapse was determined by a clinically significant increase in the intensity of erythema or in the number of papules and pustules to a point that was either intolerable to the patient or judged a relapse by the investigator. Prominence of telangiectases and dryness (roughness and scaling) were also observed.

Relapse rates during the first 6 months of treatment were compared between metronidazole and vehicle groups using the χ^2 test. Subjects who discontinued the study for reasons unrelated to treatment were considered censored and their data were not used in visits after their departure. Lesion counts and erythema were tested for significant treatment differences using the Cochran-Mantel-Haenszel test¹¹ with the investigators forming the strata. An intent-to-treat analysis was conducted for relapse rates, lesion counts, and erythema. For subjects who experienced relapse or discontinued for other reasons, lesion counts and erythema data were carried forward as data for all subsequent visits to prevent drop-out bias. Stepwise discriminant analysis with stepwise selection was used to select clinical factors that predicted relapse for subjects receiving metronidazole. The factors considered were age, inflammatory lesion counts, erythema, and dryness at the time the subjects were enrolled in the open-label portion of the study. Once the factor(s) was selected, a scatterplot was used to determine the optimal classification rule. The same data were then graphed for the vehicle-treated control subjects.

rosacea over long periods so that long-term oral antibiotic therapy can be avoided.

Topical metronidazole preparations (0.5%-1.0%) are effective treatments for rosacea.³⁻¹⁰ Sometimes, both systemic antibiotics and topical metronidazole are used together at first. Once rosacea improves, the oral antibiotic regimen may be discontinued with the hope that topical application of metronidazole will maintain the remission. The purpose of this study was to examine the effectiveness of this practice. Specifically, the efficacy of topical metronidazole was compared with its vehicle in a double-blind, vehicle-controlled trial to maintain remission of moderate to severe rosacea following the discontinuation of oral tetracycline therapy.

RESULTS

OPEN PORTION

Six investigators enrolled a total of 113 subjects with moderate to severe rosacea; 72 (64%) were women and 112 (99%) were white. The mean age was 46 years (range, 20-74 years).

At the beginning of the study, all subjects had rosacea, including centofacial erythema and papules. As

expected, both erythema scores and papule counts decreased following treatment with systemic tetracycline and topical metronidazole. The mean inflammatory lesion counts decreased from a mean (\pm SD) of 16.6 ± 10.0 to approximately 3.0 ± 6.9 , and the mean erythema decreased from moderate to mild. Of the 113 subjects who completed this phase of the study, 104 (92%) had fewer papules and/or pustules and 82 (73%) had less erythema. Combination therapy eliminated all papules/pustules in 67 subjects (59%).

Fourteen subjects (12%) withdrew from this phase of the study for reasons unrelated to treatment, and 11 (10%) did not improve enough to enter the second phase of the study that evaluated the ability of topical metronidazole to prevent or minimize exacerbations after successful treatment with combination topical and systemic therapy. Thus, 88 (78%) of the 113 subjects who started treatment were included in this second phase of the study, which called for a follow-up evaluation each month for 6 months. **Figure 1** displays the status of all 113 subjects.

DOUBLE-BLINDED PHASE

The 88 subjects were assigned to 1 of 2 treatment groups. Forty-four subjects (50%) applied metronidazole gel and

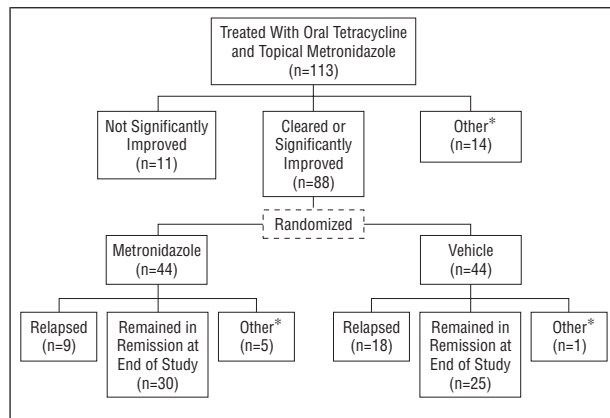


Figure 1. Status of all 113 enrolled subjects. Asterisks indicate lost to follow-up, protocol violation, patient request, and unrelated adverse effect.

Characteristics of the 88 Subjects Randomized to Receive Metronidazole Gel or Vehicle*

Characteristics	Metronidazole (n = 44)	Vehicle (n = 44)
Female	27 (61)	29 (66)
White	44 (100)	44 (100)
Mean age, y (range)	48.6 (20-74)	43.7 (29-72)
Moderate rosacea severity	40 (91)	39 (89)
Mean (SD) inflammatory lesions	0.9 (2.2)	0.5 (1.0)
Absent or mild erythema	35 (80)	32 (73)

* Values are number (percentage) except where stated otherwise.

44 subjects (50%) applied vehicle gel. The **Table** presents the demographic characteristics of the 88 subjects.

Fifty-five subjects completed the study, including 30 in the metronidazole group and 25 in the vehicle control group. Of 33 subjects who did not complete the study, 27 withdrew because of relapse. Of the other 6 subjects, 3 were lost to follow-up, 2 withdrew for personal reasons, and 1 was dropped from the study because of violation of the research protocol. Of 27 subjects who experienced relapse, 9 were treated with metronidazole gel and 18 were treated with vehicle gel. No subjects discontinued because of adverse events.

The use of topical metronidazole gel significantly prolonged the disease-free interval after therapy with oral tetracycline. The difference in relapse rates during the first 6 months of treatment between the 2 treatment groups was statistically significant; fewer subjects experienced relapse in the group treated with topical metronidazole gel ($P < .05$). Seventy-seven percent of the subjects treated with topical metronidazole did not experience relapse during the 6 months. The relapse rate of the vehicle group (18 [42%] of 43) was nearly twice that of the group treated with topical metronidazole (9 [23%] of 39) after 6 months. Of the 9 metronidazole-treated subjects who experienced relapse (23%), the relapse occurred within 3 months. The vehicle-treated subjects continued to experience relapse throughout the entire 6-month treatment period (**Figure 2**).

After combined treatment with oral tetracycline and topical metronidazole, the mean lesion counts (papules

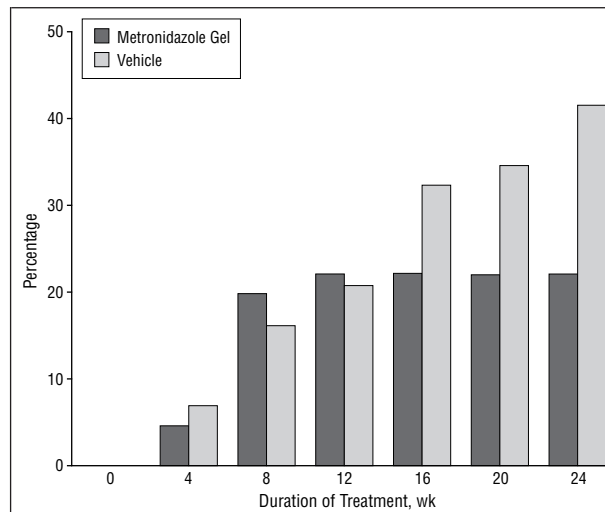


Figure 2. Cumulative percentage of subjects who experienced relapse during the double-blind vehicle-controlled phase.

and/or pustules) were 0.9 for the metronidazole group and 0.5 for the vehicle group. Approximately 75% of the subjects in both groups had no lesions at the start of the blinded phase of the study. During this phase subjects did not take tetracycline, but applied either metronidazole gel or a vehicle gel. There were no statistically significant differences in lesion counts between treatment groups in the blinded phase of the study until week 12, at which time the lesion counts were significantly less for the metronidazole-treated group ($P < .01$). The percentage of metronidazole-treated subjects with neither papules nor pustules at week 12 was 32 (74%) of 43 compared with 24 (55%) of 44 for the vehicle-treated group alone. At the end of the study, 53% of the metronidazole-treated subjects were free of papules and pustules, while only 32% of the vehicle-treated subjects remained free of lesions. The papule and/or pustule count at the end of the study (6 months) was significantly less in the metronidazole-treated group ($P < .01$). The mean number of papules and/or pustules in the metronidazole-treated group was 3.3 compared with 5.8 in the vehicle-treated group at the end of the 6-month treatment period (**Figure 3**).

Relapse of erythema was sometimes prevented by treatment with metronidazole gel. Thirty-two (74%) of 43 metronidazole-treated subjects had either no or mild erythema at the end of treatment, compared with 24 (55%) of 44 vehicle-treated subjects. While the group differences were not statistically different ($P = .14$) at end of treatment, there was a definite trend in favor of using metronidazole for maintaining low levels of erythema. The use of metronidazole did not significantly affect the number of telangiectases.

Data related to subjects applying topical metronidazole were analyzed to determine if clinical markers could identify subjects prone to relapse. The stepwise discriminant analysis identified age and dryness (at the beginning of the open portion of the study) as the 2 significant factors that would predict whether metronidazole-treated subjects would experience relapse or remain in remission. Relapses tended to occur in younger subjects

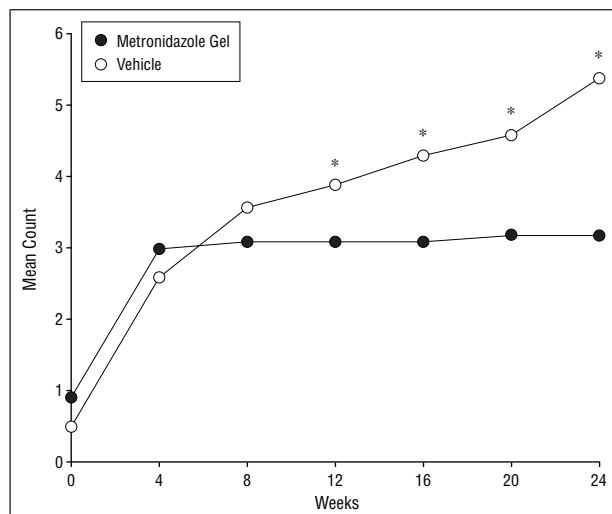


Figure 3. Mean inflammatory lesion counts of subjects during the double-blind vehicle-controlled phase. (Last value carried forward if subject withdrew early.) Asterisks indicate $P < .05$.

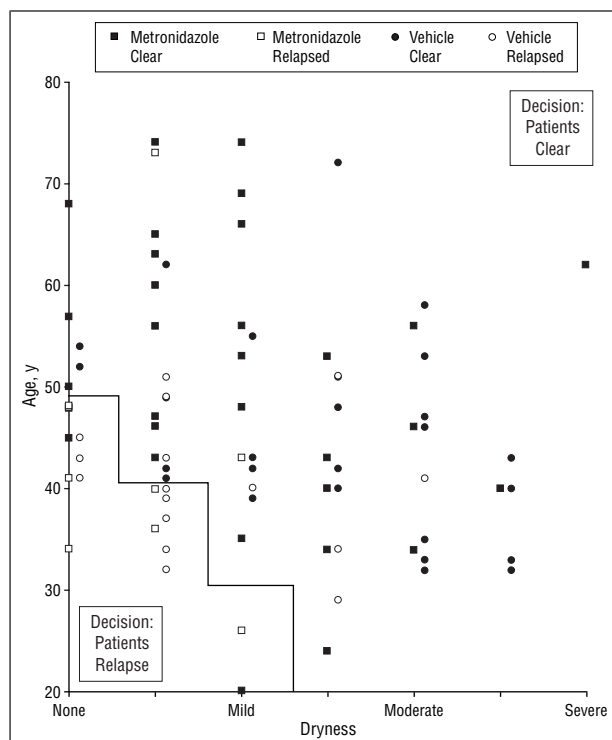


Figure 4. Scatterplot of age and dryness for subjects who experienced relapse and those who remained controlled.

with no or only mild dryness. **Figure 4** shows the scatterplot of age with dryness for metronidazole- and vehicle-treated subjects.

COMMENT

Acne rosacea usually responds well to the use of systemic antibiotics such as tetracycline. However, the tendency to develop relapses or recurrences persists for many years. While some subjects seem to require long-term systemic antibiotic therapy to maintain remission, others frequently stay well by avoiding trigger factors and apply-

ing topical medications, such as metronidazole gel. These subjects are fortunate because they avoid potential adverse effects associated with systemic antibiotic use, such as drug reactions, photosensitivity, diarrhea, and vaginal yeast infections.

The 0.75% topical metronidazole gel has been used to successfully treat mild and moderate rosacea.³⁻¹⁰ Our study determines whether twice-daily applications of topical metronidazole gel maintain a remission of acne rosacea induced by treatment with topical metronidazole gel and systemic tetracycline. The subjects in this study applied topical metronidazole gel or vehicle gel in a double-blind, vehicle-controlled study during remission. Subjects were evaluated monthly for erythema, papules, pustules, telangiectases, stinging and/or burning, pruritus, and dryness.

The group treated with the active agent, metronidazole, was significantly more likely to maintain remission of rosacea than the vehicle-treated group. Seventy-seven percent of all subjects treated with topical applications of metronidazole did not experience relapse during the 6-month study. About 53% had no papules or pustules at the 6-month end-of-study evaluation. Twenty-three percent of metronidazole-treated subjects did experience relapse. All did so within the first 3 months following discontinuation of tetracycline therapy. Forty-two percent of the vehicle-treated group experienced relapse and only 32% of subjects were free of lesions at the end of the study. Almost all (27/33) dropout subjects in both groups withdrew because of relapse: most of these subjects resumed treatment with oral antibiotics. In contrast to the metronidazole-treated group in which all relapses occurred within the first 3 months, relapses in the vehicle-treated group continued throughout the duration of the study, and possibly all may have experienced relapse if the study had continued longer. Apparently a subgroup of subjects with rosacea tends to experience relapse quickly (within 3 months) when systemic tetracycline treatment is stopped. Relapses tended to occur in younger subjects with little or no dryness (roughness or scaling).

The relapse rate in the vehicle-treated group agrees with the results of Knight and Vickers.¹² Without active treatment, about 25% of their subjects experienced relapse immediately, about 50% at 6 months, and about 70% by the end of 1 year.

Current dogma holds erythema as a primary lesion of rosacea. Dilated facial blood vessels and flushing allow fluids to leak out into the dermis to somehow induce inflammatory lesions. Control of erythema may help prevent edema, papules and pustules, and even the fibroplasia that characterizes later stages of rosacea. Topical metronidazole therapy seems able to maintain the lessened erythema produced by combined therapy with tetracycline in some subjects compared with vehicle. Perhaps metronidazole has a direct subtle effect on blood vessels, but more likely metronidazole works by stopping events leading to inflammation that may smolder without papules or pustules in untreated patients. The inflammation of papules and pustules of acne rosacea may add extra erythema. If inflammation stops, the only residual erythema is that of dilation of blood vessels. This

inflammation-induced extra vasodilation apparently lasts for some time after clinically evident inflammation ceases; therefore, prolonged remissions eventually decrease erythema to baseline. This hypothesis predicts that new inflammation, papules, and pustules would increase erythema and edema to start a vicious new cycle leading to clinical relapse. Clinical experience suggests that this is true; relapses occur quickly and new papules and pustules occur in crops.

Treatment with metronidazole did not affect telangiectases during the 6-month study. However, if control of erythema is maintained, development of further telangiectasia may be stifled. Longer studies would be necessary to establish this point, since telangiectases are a slowly developing complication of persistent and prolonged erythema.

The purpose of this study was to determine if topically applied metronidazole could maintain remission induced by systemic tetracycline and topical metronidazole. As a by-product, our study confirms that this combination therapy is an effective initial treatment for patients with rosacea. Combination treatment eliminated all papules and pustules in nearly 67 (59%) of 113 subjects. One hundred four (92%) of 113 subjects had fewer papules and pustules and 82 (73%) of 113 had less erythema. Only 11 (10%) of 113 subjects did not improve substantially with combination therapy. Also, the study established the safety of using metronidazole during a 9-month period; no subjects withdrew because of an adverse effect from the application of metronidazole gel.

In conclusion, topical metronidazole used along with systemic tetracycline produced significant improvement in 104 (92%) of 113 subjects with rosacea. Furthermore, topical metronidazole used alone without tetracycline maintained this remission for at least 6 months in about 30 (77%) of 39 subjects.

Accepted for publication February 16, 1998.

From the Department of Dermatology, University of Minnesota, Minneapolis (Dr Dahl); Minnesota Clinical Study Center, Minneapolis (Dr Katz); the Division of Dermatology,

University of Utah, Salt Lake City (Dr Krueger and Ms Weidner); the Department of Dermatology, Tulane University, New Orleans, La (Drs Millikan and Patrignelli and Mr Coleman); the Department of Dermatology, University of California at San Francisco (Drs Odom and Aly and Ms Bayles); the Department of Dermatology, Oregon Health Sciences University, Portland (Dr Parker); the Department of Dermatology, Baylor Medical Center, Houston, Tex (Dr Wolf and Ms Reusser); Southwestern Medical School, Dallas, Tex (Dr Herndon); and Galderma Laboratories Inc, Fort Worth, Tex (Drs Tuley and Czernielewski and Mr Baker). Dr Herndon is a paid consultant for Galderma Laboratories Inc. Drs Tuley and Czernielewski and Mr Baker are employees of Galderma Laboratories Inc.

This clinical research study was funded by a grant from Galderma Laboratories Inc, Fort Worth, Tex.

Reprints: Joe Willis, Galderma Laboratories Inc, 3000 Alta Mesa Blvd, Suite 300, Fort Worth, TX 76163.

REFERENCES

1. Ellis CN, Stawiski MA. The treatment of perioral dermatitis, acne rosacea and seborrheic dermatitis. *Med Clin North Am.* 1982;66:819-830.
2. Marks R. Concepts in the pathogenesis of rosacea. *Br J Dermatol.* 1968;80:170-177.
3. Dupont C. Metronidazole suspension applied topically for rosacea. *Br J Dermatol.* 1984;111:499-502.
4. Eriksson G, Nord EE. Impact of topical metronidazole on the skin and colon microflora in subjects with rosacea. *Infection.* 1987;15:8-10.
5. Nielsen PG. Treatment of rosacea with 1% metronidazole cream: a double-blind study. *Br J Dermatol.* 1983;108:327-332.
6. Nielsen PG. A double-blind study of a 1% metronidazole cream versus systemic oxytetracycline therapy for rosacea. *Br J Dermatol.* 1983;109:63-65.
7. Nielsen PG. The relapse rate for rosacea after treatment with either oral tetracycline or metronidazole cream. *Br J Dermatol.* 1983;109:122.
8. Veien NK, Christiansen JV, Hjorth N, Schmidt H. Topical metronidazole in the treatment of rosacea. *Cutis.* 1986;38:209-210.
9. Aranson IK, Rumsfield DP, West J, et al. Evaluation of topical metronidazole gel in acne rosacea. *Drug Intell Clin Pharm.* 1987;21:346-351.
10. Bleicher PA, Charles JH, Sober AJ. Topical metronidazole therapy for rosacea. *Arch Dermatol.* 1987;123:609-614.
11. Landis RJ, Heyman ER, Koch GG. Average partial association in three-way contingency tables: a review and discussion of alternative tests. *Int Stat Rev.* 1978; 46:237-254.
12. Knight AG, Vickers CFH. A follow-up of tetracycline-treated rosacea. *Br J Dermatol.* 1975;93:577-580.

Announcement

Free Patient Record Forms Available

Patient record forms are available free of charge to ARCHIVES readers by calling or writing FORMEDIC, 12D Worlds Fair Dr, Somerset, NJ 08873-9863, telephone (908) 469-7031.