

Lymphedema After Sentinel Lymph Node Biopsy for Cutaneous Melanoma

A Report of 5 Cases

David A. Wrone, MD; Kenneth K. Tanabe, MD; A. Benedict Cosimi, MD; Michele A. Gadd, MD; Wiley W. Souba, MD; Arthur J. Sober, MD

Background: Sentinel lymph node (SLN) biopsy has rapidly become the procedure of choice for assessing the lymph node status of patients with 1992 American Joint Committee on Cancer stages I and II melanoma. The procedure was designed to be less invasive and, therefore, less likely to cause complications than a complete lymph node dissection. To our knowledge, this is the first report in the literature documenting extremity lymphedema following SLN biopsy.

Observation: We report 5 cases of lymphedema after SLN biopsy in patients being routinely followed up after melanoma surgery at the Massachusetts General Hospital Melanoma Center, Boston. Three cases were mild, and 2 were moderate. Potential contributing causes of lymphedema were present in 4 patients and included the transient for-

mation of hematomas and seromas, obesity, the possibility of occult metastatic melanoma, and the proximal extremity location of the primary melanoma excision. Four of the patients underwent an SLN biopsy at our institution. We used the total number of SLN procedures ($N = 235$) that we have performed to calculate a 1.7% baseline incidence of lymphedema after SLN biopsy.

Conclusions: Sentinel lymph node biopsy can be complicated by mild and moderate degrees of lymphedema, with an incidence of at least 1.7%. Some patients may have contributing causes for lymphedema other than the SLN biopsy, but many of these causes are difficult to modify or avoid.

Arch Dermatol. 2000;136:511-514

TRADITIONAL management of patients with 1992 American Joint Committee on Cancer stage II and some cases of stage I melanoma in many centers has included elective dissection of the draining lymph node basin(s).^{1(pp38-49)} Besides the role of node dissection for accurate staging, a major reason given for performing a dissection was to improve the survival of patients with nodal disease. Such a benefit has been difficult to demonstrate. The most recent prospective randomized trial² that evaluated the role of elective lymph node dissection failed to show an overall benefit. Reluctance to accept elective node dissection for questionable therapeutic gains may have been in the past due to the morbidity associated with the procedure. Its postoperative complications include seroma and hematoma formation, wound infections, wound separations, pain and nerve dysfunction, skin slough, flap necrosis, and lymphedema.³⁻⁸

Morton et al⁹ developed a technique that would reduce the need for lymph node dissections and thus the associated mor-

bidity for most patients. This technique, eventually referred to as sentinel lymph node (SLN) biopsy, identifies the initial draining lymph node(s) in a lymph basin.¹⁰ It was proposed, and later validated, that if the SLN shows no evidence of metastatic melanoma, then the remainder of the lymph nodes in the basin are also highly likely free of disease.¹⁰⁻¹² Thus, patients with negative SLN biopsy results can be spared a complete lymph node dissection.

Since the SLN biopsy offers an effective means of identifying metastatic melanoma in regional lymph nodes, it has become the staging procedure of choice for patients with stage II and higher-risk stage I melanoma.¹³ Staging is important for considerations of giving adjuvant therapy, for enrollment in investigational protocols, and for its prognostic value.^{13,14}

The SLN biopsy should have a lower rate of complications than complete dissections, because it is a less invasive procedure. The experience at our center supports this belief, but SLN biopsy does carry some risk. We describe 5 patients with lymphedema. To our knowledge, this is the first report in the literature of clearly docu-

From the Massachusetts General Hospital Melanoma Center (Drs Wrone, Tanabe, Cosimi, Gadd, Souba, and Sober), and the Departments of Dermatology (Drs Wrone and Sober) and Surgery (Drs Tanabe, Cosimi, Gadd, and Souba), Massachusetts General Hospital, Boston.

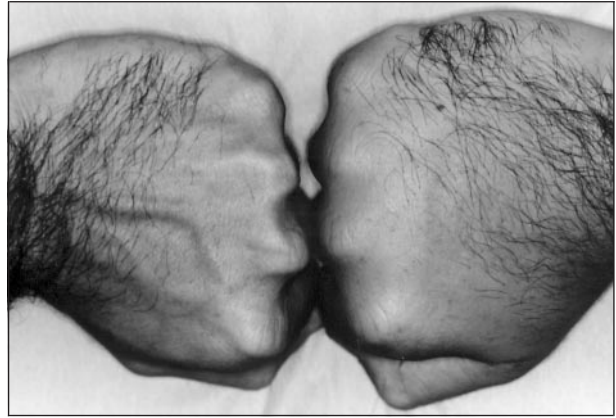
PATIENTS AND METHODS

We identified clinically significant lymphedema after SLN biopsy in patients being routinely followed up after melanoma surgery at the Massachusetts General Hospital Melanoma Center, Boston. This report is not necessarily a complete listing of patients with lymphedema or other complications. The center is a multidisciplinary tertiary referral unit that includes surgeons, dermatopathologists, dermatologists, and medical oncologists. We have performed 235 SLN biopsies through November 1, 1998. Most, but not necessarily all, of these patients have been seen in follow-up. The patient base is diverse and includes a significant number of patients who have had the definitive primary surgery, including SLN biopsy, performed elsewhere. We categorized the severity of edema as mild, moderate, or severe. Mild edema was usually noted only by the physician and did not affect the patient clinically. The physician and patient identified moderate edema. It was associated with at least some discomfort. Severe edema was defined as clinically obvious disabling edema that made activities of daily living difficult.

mented extremity lymphedema after SLN biopsy. One SLN biopsy review¹⁵ mentions a case of "transient postoperative lymphedema of the extremities" in the "Results" section of its "abstract," but no further comments about lymphedema are made in the article.

RESULTS

We report 5 cases of lymphedema after SLN biopsy. Lymphedema was found in 2 women and 3 men (average age, 51 years; range, 37-59 years). The results of the primary biopsy showed 4 superficial spreading melanomas and 1 nodular melanoma or a possible metastatic nodule (primary site unknown). Patients 2 and 5 had primary melanomas and excisions on their backs. Patient 1 had a primary melanoma on his right shoulder. Patients 3 and 4 had distal lower extremity primary melanomas. The average Breslow tumor thickness was 2.16 mm (range, 0.80-4.00 mm). Three axillary and 2 inguinal SLN biopsies were performed. The average number of lymph nodes removed was 2.4 (range, 1-7). The average incision size was 3.5 cm (range, 2.2-5.0 cm). Four patients had normal lymph nodes, as determined by histopathologic examination. One lymph node showed microscopic metastatic disease; this patient (patient 3) chose not to undergo a complete lymph node dissection. She had no clinical adenopathy at her last examination 6 months following SLN biopsy. The postoperative course in all 5 patients, other than lymphedema, was without major problems. Patient 3 had a 2.5-cm hematoma after the SLN biopsy. It resolved spontaneously within 4 weeks. Patient 2 had a seroma that was successfully drained with needle aspiration. Patient 5 had mild paresthesias in an ulnar distribution after his right axillary SLN biopsy. The paresthesias



Patient 5. The prominent edema on his right hand obscured his superficial dorsal veins. He had moderate edema, as determined by physical examination and medical history. We could not identify contributing factors other than sentinel lymph node biopsy as a cause for this patient's lymphedema.

thesias were still present at his last examination, 3 months after the procedure. Potentially relevant comorbid histories were present in 3 patients. Patient 4 had a resected invasive breast carcinoma treated with tamoxifen citrate. The lymphedema being reported was in the left lower extremity following SLN biopsy of the left groin. Patient 1 had a long history of fibromyalgia. Of the 5 patients, 4 were described as being of normal weight. However, 1 patient (patient 3) was moderately overweight. He weighed 98 kg and was 1.8 m tall. No patient had a recent or distant history of keloidal scarring, wound healing problems, cellulitis, or significant antecedent trauma to the edematous limb.

Edema developed on average 6 weeks after SLN biopsy (range, 2-10 weeks). Its severity was mild in patients 1, 2, and 3 and did not interfere with their daily activities. Patient 2 initially had moderate edema, but severity decreased over 6 months to a mild level. Two patients have moderate edema. Patient 5 felt impaired by his hand edema, stating that it is difficult for him to grasp objects such as a tennis racket. His moderate swelling is noted in the **Figure**. Patient 4 complains that by the end of the day discomfort forces her to elevate her leg. The swelling makes her right shoe feel uncomfortably tight. A recent trial of support hose dramatically reduced her symptoms.

The baseline incidence of lymphedema seen after SLN biopsy at our institution is 1.7%. We calculate the incidence using the number of cases of lymphedema ($n = 4$) divided by the total number of SLN biopsies performed at the center ($N = 235$). We excluded patient 3 from the calculation because she had surgery at another institution.

COMMENT

Sentinel lymph node biopsy can be associated with mild and moderate degrees of lymphedema. The procedure appears to be a major cause of the lymphedema in the patients in this study, but contributing factors do exist for 4 of the 5 patients described. Lack of surgical experience with the technique is unlikely to explain the edema

in all of our patients. In their classic study, Morton et al⁹ used only vital blue dye to isolate the initial draining lymph node(s). Finding this SLN was challenging. They suggested that a learning experience of at least 60 patients was needed to gain proficiency with the technique.⁹ The addition of radiocolloid along with vital blue dye to isolate the SLN has made the procedure simpler and has reduced the extent of exploratory surgical dissection.¹⁰ Patients 1, 2, 4, and 5 underwent the procedure at our institution, and the procedure was performed by experienced surgeons using radiocolloid and vital blue dye. The SLN biopsy of patient 3 was performed at another institution. This patient's procedure used radiocolloid and vital blue dye.

Underlying medical conditions may contribute to the lymphedema seen in 3 of our patients. Patient 4 had breast cancer, but lymphedema of her left leg cannot be explained by breast cancer surgery or chemotherapy. The SLN of patient 3 had a small focus of microscopic melanoma, and the remaining lymph nodes were not resected. The results of a clinical examination 6 months after the SLN biopsy revealed no evidence of metastatic melanoma, but she may have microscopic nodal disease. She is the only patient with stage III cancer in our study and thus has the highest chance of disease advancement, particularly during the first postoperative year.^{1(pp11-35)} If her remaining lymph nodes develop microscopic metastatic melanoma, they may contribute to lymphedema. Patient 1 had fibromyalgia. An examination of patients with fibromyalgia typically shows no abnormalities other than tenderness at points on the body.^{16,17} Fibromyalgia may be associated with alterations in immune function, but lymphedema has not been reported.¹⁸ Thus, the localized lymphedema in patient 1 is in all likelihood unrelated to fibromyalgia. These case reports are insufficient to draw conclusions about risk factors for lymphedema. A previous study⁸ suggested that age and obesity were risk factors for edema after traditional nodal dissection. Four of the patients were in their 50s. One patient (patient 3) was moderately obese. He weighed 98 kg and was 1.8 m tall.

The primary surgical excision may have contributed to the lymphedema in 1 patient. Patient 1 had an 8.5 × 3.5-cm elliptical excision of his right shoulder melanoma. The resulting scar was vertical and was centered on the skin at the midpoint of his right clavicle. This excision alone may explain the edema on his right arm. It is less likely that the primary excision contributed to lymphedema in the other 4 patients. Patient 4 had a 4.4-cm-diameter circular excision to fascia of her primary melanoma centered on the skin over her tendo calcaneus. The defect was repaired with a split-thickness skin graft. The patient noted no edema after the surgery. Seven weeks later, she underwent an SLN biopsy and developed edema on her dorsal foot. The SLN biopsy temporally correlates with her lymphedema. The excisions on patients 2 and 5 were on the back. Patient 4 had edema of her right ankle, but the primary melanoma was distal to this site on her right dorsal foot.

The postoperative course in 2 patients may have contributed to their lymphedema. Patients 2 and 3 developed a seroma and a hematoma, respectively. The se-

roma resolved with needle aspiration, while the hematoma spontaneously resolved. Both collections were less than 3 cm in diameter, but they may have induced fibrosis or other changes to the lymph node basin. Both patients followed their surgeons' suggestions to limit movement of their affected limb for several weeks after the SLN biopsy.

Lymphedema is seen in at least 1.7% of patients who undergo SLN biopsy at our institution. The incidence may be greater, because we may not have complete follow-up data on all patients. However, it is probably lower than the incidence of lymphedema after complete lymph node dissection. After a traditional lymph node dissection, lymphedema is considerable and varies markedly by site. Lymphedema after axillary dissection ranges from 1% to 12%.^{6,8} Inguinal dissections carry a higher rate of lymphedema, ranging from 22% to 41%.^{3-5,8} Unfortunately, previous studies^{3-6,8} on lymphedema do not include information on the severity of edema observed. It is our experience that the incidence and severity of lymphedema after SLN biopsy is much lower than that following complete lymph node dissection.

Developments in medical oncology may reduce the need for SLN biopsies. Recently, a randomized trial¹⁹ has shown a benefit of interferon alfa-2b in patients with stage II melanoma. If the validity of this trial can be confirmed, especially in surgically staged patients, some patients may be treated with interferon therapy regardless of the presence of microscopic metastatic lymph node disease. However, the SLN biopsy procedure may still retain value for its prognostic abilities.^{1(pp11-35),13} Also, a recent study²⁰ has suggested that patients with occult metastatic lymph node disease may benefit from a complete lymph node dissection. The SLN biopsy could be used to identify this subgroup of patients.

In summary, SLN biopsy was a major cause of the lymphedema in the 5 patients described. It occurs with an incidence of at least 1.7%. Some patients may have contributing causes for lymphedema other than the SLN biopsy, but these causes are difficult to modify or avoid. Reduction of seroma or hematoma formation may reduce the likelihood of lymphedema formation in some patients. Weight reduction in obese patients may decrease the likelihood of lymphedema formation, but the time from diagnosis of melanoma to the time of SLN biopsy is frequently short.

Accepted for publication August 28, 1999.

This study was supported in part by the Marion Gardner Jackson Trust, Bank of Boston, Boston, Mass.

Corresponding author: Arthur J. Sober, MD, Department of Dermatology, Massachusetts General Hospital, Bartlett 622, Boston, MA 02114 (e-mail: asober@partners.org).

REFERENCES

1. Balch CM, Houghton AN, Sober AJ, Soong S-J, eds. *Cutaneous Melanoma*. 3rd ed. St Louis, Mo: Quality Medical Publishing Inc; 1998.
2. Balch CM, Soong S-J, Bartolucci AA, et al. Efficacy of an elective regional lymph node dissection of 1 to 4 mm thick melanomas for patients 60 years of age and younger. *Ann Surg*. 1996;224:255-263.
3. Karakousis CP, Emrich LJ, Rao U. Groin dissection in malignant melanoma. *Am J Surg*. 1986;152:491-495.

4. Dasmahapatra KS, Karakousis CP. Therapeutic groin dissection in malignant melanoma. *Surg Gynecol Obstet.* 1983;156:21-24.
5. Harris MN, Gumpert SL, Berman IR, Bernard RW. Ilioinguinal lymph node dissection for melanoma. *Surg Gynecol Obstet.* 1973;136:33-39.
6. Harris MN, Gumpert SL, Maiwandi H. Axillary lymph node dissection for melanoma. *Surg Gynecol Obstet.* 1972;135:936-940.
7. Bland KI, Klamer TW, Polk HC Jr, Knutson CO. Isolated regional lymph node dissection: morbidity, mortality and economic considerations. *Ann Surg.* 1981;193:372-376.
8. Urist MM, Maddox WA, Kennedy JE, Balch CM. Patient risk factors and surgical morbidity after regional lymphadenectomy in 204 melanoma patients. *Cancer.* 1983;51:2152-2156.
9. Morton DL, Wen DR, Wong JH, et al. Technical details of intraoperative lymphatic mapping for early stage melanoma. *Arch Surg.* 1992;127:392-399.
10. Krag DN, Meijer SJ, Weaver DL, et al. Minimal-access surgery for staging of malignant melanoma. *Arch Surg.* 1995;130:654-658.
11. Reintgen D, Cruse CW, Wells K, et al. The orderly progression of melanoma nodal metastases. *Ann Surg.* 1994;220:759-767.
12. Ross MI, Reintgen D, Balch CM. Selective lymphadenectomy: emerging role for lymphatic mapping and sentinel node biopsy in the management of early stage melanoma. *Semin Surg Oncol.* 1993;9:219-223.
13. Tanabe KK, Reintgen D. The role of sentinel lymph node mapping for melanoma. *Adv Surg.* 1997;31:79-103.
14. Kirkwood JM, Strawderman MH, Ernstoff MS, et al. Interferon alfa-2b adjuvant therapy of high-risk resected cutaneous melanoma: the Eastern Cooperative Oncology Group Trial EST 1684. *J Clin Oncol.* 1996;14:7-17.
15. Cottingham T, Larson J, Delaney JP, Zachary C. Sentinel node dissection in the treatment of melanoma: report of three cases and review of the literature. *Dermatol Surg.* 1997;23:113-118.
16. Bluestein HG. Periarticular rheumatic complaints. In: Stein JH, ed. *Internal Medicine.* 5th ed. St Louis, Mo: Mosby-Year Book Inc; 1998:1195-1196.
17. Wolfe F, Smythe HA, Yunus MB, et al. The American College of Rheumatology 1990 Criteria for the Classification of Fibromyalgia: report of the Multicenter Criteria Committee. *Arthritis Rheum.* 1990;33:160-172.
18. Buchwald D. Fibromyalgia and chronic fatigue syndrome: similarities and differences. *Rheum Dis Clin North Am.* 1996;22:219-243.
19. Pehamberger H, Soyer HP, Steiner A, et al. Adjuvant interferon alfa-2a treatment in resected primary stage II cutaneous melanoma: Austrian Malignant Melanoma Cooperative Group. *J Clin Oncol.* 1998;16:1425-1429.
20. Cascinelli N, Morabito A, Santinami M, et al. Immediate or delayed dissection of regional nodes in patients with melanoma of the trunk: a randomised trial: WHO Melanoma Programme. *Lancet.* 1998;351:793-796.

News and Notes

The Committee on International Affairs of the American Academy of Dermatology is seeking to develop a clearinghouse of opportunities for dermatologists to serve in clinics in developing countries for short durations of a few weeks to a month. If you know of such opportunities, please send the information to the American Academy of Dermatology, PO Box 4014, Schaumburg, IL 60168-4014, Attention: Debra Kroncke. Fax: 847-330-0050; e-mail: dkroncke@aad.org.