

# Effect of Carbon Dioxide Laser Resurfacing on Epidermal p53 Immunostaining in Photodamaged Skin

Jeffrey S. Orringer, MD; Timothy M. Johnson, MD; Sewon Kang, MD; Darius J. Karimipour, MD; Craig Hammerberg, PhD; Ted Hamilton, MS; John J. Voorhees, MD, FRCP; Gary J. Fisher, PhD

**Objective:** To quantitatively examine changes in p53 tumor suppressor gene immunostaining after carbon dioxide (CO<sub>2</sub>) laser resurfacing of photodamaged skin to assess the potential value of this treatment in reducing the risk of progression to cutaneous carcinoma.

**Design:** Serial in vivo immunohistochemical analyses after laser therapy.

**Setting:** Academic referral center, Department of Dermatology, University of Michigan, Ann Arbor.

**Other Participants:** Volunteer sample of 11 adults, 51 to 76 years old, with clinically evident photodamage of the forearms.

**Intervention:** Focal CO<sub>2</sub> laser resurfacing of photodamaged forearms and serial biopsies at baseline, 3 weeks, and 6 months after treatment.

**Main Outcome Measures:** Because keratinocytes with mutations in p53 or altered p53 expression stain via immunohistochemical techniques, image analysis of im-

munochemically stained sections was used to quantify p53 expression.

**Results:** Positive immunostaining for p53 in the interfollicular epidermis was noted in 8 of 11 subjects at baseline, with an average staining density of 250 cells/mm<sup>2</sup>. Average staining decreased to 3 cells/mm<sup>2</sup> 3 weeks after treatment. This decrease was sustained at 5 cells/mm<sup>2</sup> 6 months after resurfacing.

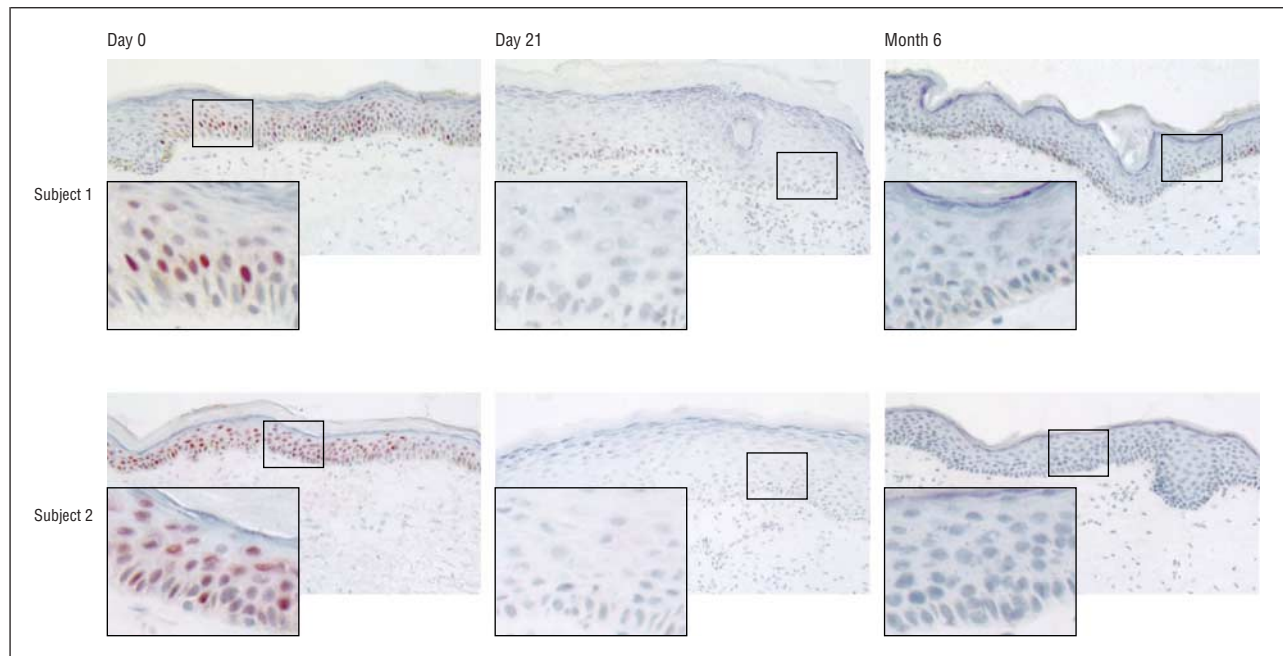
**Conclusions:** There was a consistent decrease in p53 immunostaining in the interfollicular epidermis lasting for at least 6 months after CO<sub>2</sub> laser resurfacing of photodamaged skin. Since p53 mutation or overexpression is observed in a majority of cases of cutaneous carcinoma, the posttreatment repopulation of the epidermis with p53-negative keratinocytes should theoretically decrease the risk of malignant progression. Further study of laser resurfacing as a prophylactic procedure in patients at high risk for skin cancer development appears warranted.

*Arch Dermatol.* 2004;140:1073-1077

From the Departments of Dermatology (Drs Orringer, Johnson, Kang, Karimipour, Hammerberg, Voorhees, and Fisher and Mr Hamilton), Surgery (Section of Plastic Surgery) (Dr Johnson), and Otorhinolaryngology (Dr Johnson), University of Michigan Medical School, Ann Arbor. The authors have no relevant financial interest in this article.

**C**ARBON DIOXIDE (CO<sub>2</sub>) LASER resurfacing is a frequently used therapeutic modality for improving the appearance of photodamaged skin, and it has also been reported to be successful in the treatment of a number of benign cutaneous lesions.<sup>1-4</sup> Its utility in the eradication of and prophylaxis against premalignant lesions and superficial cutaneous carcinomas remains more controversial.<sup>5-8</sup> There is a general scarcity of literature that evaluates the effectiveness of CO<sub>2</sub> laser resurfacing in treating actinic keratoses or other signs of premalignancy, and most of the studies on this subject to date are mainly clinical. We, therefore, sought to assess the effects of CO<sub>2</sub> laser therapy on photodamaged skin from a quantitative immunohistochemical perspective.

Mutations in the tumor suppressor gene, p53, are highly associated with cutaneous squamous cell carcinoma and actinic keratoses.<sup>9-12</sup> (We are aware of the recent controversy in the literature regarding whether to categorize actinic keratoses as a subtype of squamous cell carcinoma or simply a precursor lesion, but the following analysis of the effects of laser resurfacing on p53 staining would hold regardless of this classification.<sup>9,13</sup>) In addition, Jonason et al<sup>14</sup> reported the frequent existence of clonal populations of p53-mutated keratinocytes in noncancerous skin, which are found at a higher frequency in sun-exposed areas. Given the "multiple-hit" theory of carcinogenesis, nonmalignant keratinocytes with p53 mutations are likely at a higher risk of neoplastic progression and, ultimately, transformation to invasive skin cancer. Thus,



**Figure 1.** Micrographs showing p53 immunohistochemical staining of skin samples from 2 subjects. Density of p53-positive cellular staining was decreased after carbon dioxide laser resurfacing in photodamaged human skin (original magnification  $\times 100$ ; insets  $\times 325$ ).

the presence of *p53* mutations may serve as a marker for both photodamage and an elevated risk of developing cutaneous carcinoma.<sup>15</sup>

Furthermore, recent work by El-Domyati et al<sup>16</sup> demonstrated enhanced expression of wild-type p53 in sun-exposed skin that was more pronounced in older subjects. This was associated with a decrease in the number of apoptotic cells in skin examined by biopsy with advancing age in sun-exposed areas. The decrease in apoptotic cells was thought to potentially impact the proliferation-apoptosis balance in affected skin, and thus it was postulated to potentially play a role in tumorigenesis. Therefore, even the presence of enhanced expression of wild-type p53 in photodamaged skin may suggest a precancerous state or at least an elevated risk of skin cancer formation.

Both mutations in the *p53* gene and the increased expression of wild-type p53 protein found in photodamaged human skin are detectable by immunohistochemical techniques.<sup>14,17,18</sup> We reasoned that the number of p53-positive keratinocytes could serve as an indicator of the extent of a premalignant state in tissue studied by biopsy. In this study, we examined changes in p53 immunostaining after CO<sub>2</sub> laser resurfacing of clinically photodamaged skin to assess the potential value of this treatment in minimizing the risk of progression to cutaneous carcinoma.

## METHODS

This study was approved by the institutional review board of the University of Michigan Medical School, Ann Arbor, and informed consent was obtained from all study subjects. Tissue was obtained from subjects participating in a clinical trial studying the effects of pretreatment with tretinoin on wound healing after CO<sub>2</sub> laser resurfacing (authors' unpublished data, 2004). Subjects aged 51 to 76 years with clinically evident pho-

todamage of the forearms were recruited. This was a prospective, randomized, blinded clinical trial during which subjects' forearms were focally treated with a CO<sub>2</sub> laser (Ultrapulse; Coherent Inc, Santa Clara, Calif) after a 3-week period of serial applications of tretinoin to one forearm and a placebo (identical vehicle cream without the retinoid) to the other forearm. *Only data derived from the biopsy specimens obtained from placebo-treated forearms are included in this article.* The CO<sub>2</sub> laser settings used include 300 mJ and 60 W with computer pattern generator settings of 3/5/6 and/or 3/5/9. Of note, subjects were specifically instructed to avoid sun exposure both before the procedure and during the period of reepithelialization of the wounds. Punch biopsy specimens (3 mm) were obtained at baseline and at day 21 after laser resurfacing (after reepithelialization had occurred) in all subjects, and at 6 months after treatment in 6 of the patients. Immunohistochemical staining for p53 was performed, and image analysis was used to quantify the number of positive-staining cells. These studies used p53 monoclonal antibody DO-7 (DAKO Corp, Carpinteria, Calif). Staining was performed as previously described.<sup>19</sup>

Changes in p53 immunostaining, as measured by the number of positive cells per square millimeter, were evaluated at 3 weeks and 6 months after CO<sub>2</sub> laser treatment, relative to pretreatment levels, by means of repeated-measures analysis of variance. Mean levels at each of the 2 posttreatment time points were compared with pretreatment levels by Dunnett test. The type I error rate was set at .05. Summary statistics include minimum and maximum values, means, and standard errors. The data were analyzed with SAS statistical software (SAS Institute Inc, Cary, NC).

## RESULTS

Before treatment, positive immunostaining for p53 was noted in 8 of 11 subjects. The p53-positive cells were observed in basal and suprabasal keratinocytes, in clusters and throughout the interfollicular epidermis (**Figure 1**). Among subjects with positive staining, image analysis

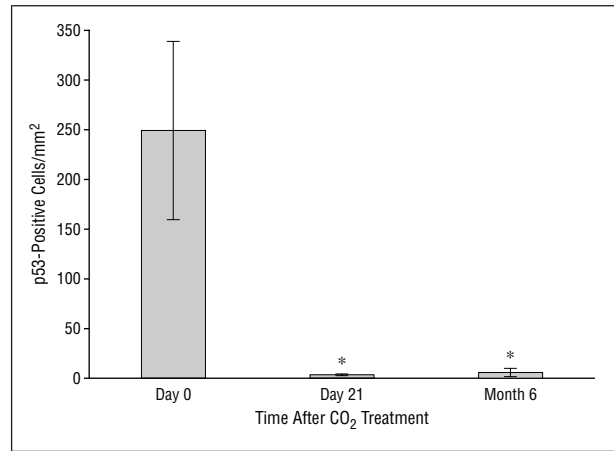
showed an average staining density of 250 stained cells per square millimeter (**Figure 2**). Staining density was reduced to an average of 3 cells/mm<sup>2</sup> after reepithelialization of the CO<sub>2</sub> laser–induced wounds, on day 21 after laser resurfacing. Thus, the density of p53-positive cells was reduced to approximately 1% of the pretreatment level. Among the 6 subjects who consented to provide additional tissue samples 6 months after treatment, average staining density remained decreased at an average of 5 cells/mm<sup>2</sup>, or 2% of the pretreatment level (Figure 2). The changes noted were statistically significant.

## COMMENT

Cancer is thought to develop through a series of genetic “hits” to previously normal tissue, which progresses from a premalignant state to invasive malignancy. One such genetic hit is mutation of the *p53* tumor suppressor gene, a common occurrence in cutaneous carcinomas that facilitates the accumulation of subsequent mutations.<sup>12,20,21</sup> A therapeutic modality that decreases the number of keratinocytes containing *p53* mutations should reduce the risk of malignant progression to invasive skin cancer.

Because of the well-known ability of CO<sub>2</sub> laser resurfacing to reproducibly remove the entire interfollicular epidermis, this procedure should eliminate a large percentage of the *p53*-mutated keratinocytes in treated skin. If the repopulating keratinocytes are negative for *p53* mutations, the risk of skin cancer development should be reduced. In fact, a previous study suggests that the regenerated epidermis seen after healing of CO<sub>2</sub> laser–induced wounds in photodamaged skin is without significant histologically detectable atypia, and previous clinical studies have reported the successful elimination of actinic keratoses and superficial skin cancers with this treatment.<sup>6,7,22</sup> Various other procedures, including chemical peels and dermabrasion, have similarly been purported to be useful in the prophylactic treatment of actinically damaged skin.<sup>23</sup> However, there are also reports in the literature that suggest that ablative laser resurfacing may not be particularly efficacious for the treatment of premalignant or malignant lesions associated with actinic damage. For example, Fulton et al<sup>8</sup> described the fairly frequent (14.3%) development of actinic keratoses or basal cell carcinomas within 1 year among 35 patients who underwent CO<sub>2</sub> laser resurfacing.

Given that the value of CO<sub>2</sub> laser resurfacing when used as prophylaxis against the development of actinic keratoses and cutaneous carcinomas remains controversial, we sought to establish objective, quantitative evidence to substantiate this potential role for the procedure. El-Domyati and coworkers<sup>24</sup> recently reported a similar approach in examining the effects of tretinoin therapy, superficial chemical peeling, and dermabrasion on *p53* immunostaining. In our study, there was a consistent decrease in *p53*-positive cells in the interfollicular epidermis as compared with baseline in laser-treated photodamaged skin. This was sustained for at least 6 months after a single 2-pass CO<sub>2</sub> laser resurfacing procedure. It has been demonstrated that *p53* mutations usually lead to immunopositivity.<sup>25</sup> To the extent that *p53* immunostaining is a reliable indicator of mutations in



**Figure 2.** Effect of carbon dioxide laser resurfacing on *p53* immunostaining. Resurfacing significantly decreased *p53* immunostaining at 3 weeks and 6 months after treatment compared with baseline (asterisk;  $P < .05$ ). Bars indicate means; limit lines, standard errors.

the *p53* gene, the reduced number of keratinocytes with abnormal *p53* expression should, as noted above, decrease the risk of neoplastic progression to skin cancer because cells with at least 1 previously detectable genetic hit have been eliminated by the procedure.

In addition, elevated expression of positively staining wild-type *p53* in sun-exposed skin has been described and is associated with a decrease in cellular apoptosis.<sup>16</sup> We postulate that this may also suggest a precancerous state and/or serve as a marker for chronic photodamage. Thus, the elimination of even wild-type *p53* overexpression (as defined by immunopositivity) may have some prophylactic benefit. In this pilot study, *p53*-positive keratinocytes were found both clustered (suggesting mutant *p53*) and more diffusely scattered throughout the interfollicular epidermis (suggesting wild-type *p53*) before laser resurfacing. Staining in both clustered and/or diffuse patterns was nearly eliminated by the treatment. The removal of clustered clones of *p53*-mutant keratinocytes is clearly suggestive of some prophylactic benefit, but the impact of decreasing the number of cells overexpressing wild-type *p53* is less clear.

It should be noted that *acute* exposure to ultraviolet irradiation may transiently increase expression of positively staining wild-type *p53*.<sup>11,26,27</sup> To minimize such acute effects, we asked subjects to avoid sun exposure, both before resurfacing and during the period of reepithelialization after the treatment. Although such acute sun exposure would not impact the demonstration of mutant *p53*, it is possible that some of the *p53* expression detected before resurfacing (especially in nonclustered cells) could have been due to recent sun exposure, and may therefore be wild-type *p53*. The benefits of eliminating such sunlight-induced wild-type *p53* expression are again not clear at this time.

The potential prophylactic benefit of CO<sub>2</sub> laser resurfacing would likely be even more profound if this procedure proves to destroy premalignant epidermal stem cells.<sup>28,29</sup> There is controversy in the literature regarding whether these cells reside in the interfollicular basal layer, exclusively in the bulge region of the hair follicle, or in both locations.<sup>30</sup> We cannot comment on the ability of

CO<sub>2</sub> laser therapy to affect follicularly based stem cells. However, as some stem cells likely reside in the inter-follicular epidermis, we can speculate that the treatment eliminates some p53-mutated stem cells, given the essentially complete loss of p53-staining cells after treatment. This is in keeping with recent work by Urato et al,<sup>31</sup> who analyzed DNA derived from putative epidermal stem cell colonies for mutations in exon 7 of the p53 gene in actinically damaged facial skin of patients undergoing CO<sub>2</sub> laser resurfacing. In that study, among all 8 subjects who had such mutations at baseline, none showed exon 7 p53 mutations after the procedure. It was hypothesized that, after removal of photodamaged interfollicular stem cells via laser resurfacing, reepithelialization from photoprotected hair follicle-derived stem cells resulted in the findings noted by Urato et al.<sup>31</sup>

It is vital to note that the potential prophylactic benefit of ablative laser therapy does not imply that treated areas are free of the risk of developing skin cancer. Premalignant and/or malignant follicular epithelial cells or interfollicular epidermal cells originally found lateral to the treated skin may still migrate into the laser-treated area, providing the basis for the development of actinic keratoses, squamous cell carcinomas, or basal cell carcinomas. In addition, clinically undetectable but preexisting skin cancers located deep to the area treated by the laser may ultimately become evident. Furthermore, inadvertent incomplete resurfacing could also allow a small number of residual mutant cells to proliferate. However, because "risk" is by definition a question of numbers, the treatment would be expected to have prophylactic value by simply lowering the likelihood that a p53-mutated cell completes the transformation into a malignant cell, because of the diminished numbers of such cells remaining after cutaneous resurfacing. Thus, development of actinic keratoses or clinically significant cutaneous carcinomas after CO<sub>2</sub> laser resurfacing may not indicate a complete failure of the procedure's prophylactic utility, but rather may be a matter of some patients losing the "numbers game," as we might expect. For example, although it is somewhat discouraging that 5 of 35 patients in the series reported by Fulton et al<sup>8</sup> developed actinic keratoses or basal cell carcinomas within 12 months of laser resurfacing, given that these patients were described as having "extreme" sun damage, it may be that more of the subjects would have developed similar lesions or that the 5 "failures" would have developed greater numbers of lesions without the treatment. Additional controlled clinical studies are required to address these possibilities.

Despite clinically evident photodamage in all of our study subjects, only 8 of 11 had significant p53-positive staining before resurfacing. To the extent that we have assessed the potential prophylactic benefit of ablative laser resurfacing with respect to p53 immunostaining specifically, we cannot comment on the value of the treatment, if any, to subjects who did not have p53-positive keratinocytes at baseline. It may be that any number of other significant epidermal genetic mutations are eliminated by the treatment, but this is purely speculative.

The forearms were used as our treatment site in this study because of practical limitations in the number of

skin samples that could be obtained from the face. While there may be minor differences in the ways photodamaged forearm and facial skin respond to laser resurfacing, there is no reason to believe that fundamental wound healing mechanisms are different at these sites. However, we cannot exclude the possibility that p53 immunostaining might be altered by ablative laser resurfacing in a different fashion in facial skin than was demonstrated in this study using forearm skin.

Finally, it must be noted that this is a preliminary study based on a fairly small number of subjects. If alterations in p53 immunostaining are ultimately used to assess the utility of CO<sub>2</sub> laser resurfacing as a prophylactic procedure in terms of the development of cutaneous malignancy, greater numbers of patients, studied for even longer posttreatment periods, will be necessary. Additional studies assessing the correlation between p53 immunoreactivity and mutations will also be warranted. Furthermore, evaluating variations in treatment parameters based on patient characteristics (the presence of hyperthrophic actinic keratoses, for example) may also be of value. The results of the present study suggest that additional work in this area is warranted.

Accepted for publication March 5, 2004.

This study was supported by a research grant from the Dermatology Foundation, Evanston, Ill.

Correspondence: Jeffrey S. Orringer, MD, Department of Dermatology, University of Michigan Health Systems, 1910 Taubman Center, 1500 E Medical Center Dr, Ann Arbor, MI 48109-0314 (jorringer@umich.edu).

## REFERENCES

1. Fitzpatrick RE, Goldman MP, Ruiz-Esparza J. Clinical advantage of the CO<sub>2</sub> laser superpulsed mode: treatment of verruca vulgaris, seborrheic keratoses, lentigenes, and actinic cheilitis. *J Dermatol Surg Oncol.* 1994;20:449-456.
2. Alster TS, Garg S. Treatment of facial rhytides with a high-energy pulsed carbon dioxide laser. *Plast Reconstr Surg.* 1996;98:791-794.
3. Fitzpatrick RE. Laser resurfacing of rhytides. *Dermatol Clin.* 1997;15:431-447.
4. Waldorf HA, Kauvar AN, Geronemus RG. Skin resurfacing of fine to deep rhytides using a char-free carbon dioxide laser in 47 patients. *Dermatol Surg.* 1995;21:940-946.
5. Stratigos AJ, Tahan S, Dover JS. Rapid development of nonmelanoma skin cancer after CO<sub>2</sub> laser resurfacing. *Arch Dermatol.* 2002;138:696-697.
6. Trimas SJ, Ellis DA, Metz RD. The carbon dioxide laser: an alternative for the treatment of actinically damaged skin. *Dermatol Surg.* 1997;23:885-889.
7. Massey RA, Eliezri YD. A case report of laser resurfacing as a skin cancer prophylaxis. *Dermatol Surg.* 1999;25:513-516.
8. Fulton JE, Rahimi AA, Helton P, Dahlberg K, Kelly AG. Disappointing results following resurfacing of facial skin with CO<sub>2</sub> lasers for prophylaxis of keratoses and cancers. *Dermatol Surg.* 1999;25:729-732.
9. Ashton KJ, Weinstein SR, Maguire DJ, Griffiths LR. Chromosomal aberrations in squamous cell carcinoma and solar keratoses revealed by comparative genomic hybridization. *Arch Dermatol.* 2003;139:876-882.
10. Sarasin A, Giglia-Mari G. p53 Gene mutations in human skin cancers. *Exp Dermatol.* 2002;11(suppl 1):44-47.
11. Ling G, Chadwick CA, Berne B, Potten CS, Ponten J, Ponten F. Epidermal p53 response and repair of thymine dimers in human skin after a single dose of ultraviolet radiation: effects of photoprotection. *Acta Derm Venereol.* 2001;81:81-86.
12. Brash DE, Ponten J. Skin precancer. *Cancer Surv.* 1998;32:69-113.
13. Lober BA, Lober CW, Accola J. Actinic keratosis is squamous cell carcinoma. *J Am Acad Dermatol.* 2000;43:881-882.
14. Jonason AS, Kunala S, Price GJ, et al. Frequent clones of p53-mutated keratinocytes in normal human skin. *Proc Natl Acad Sci U S A.* 1996;93:14025-14029.
15. de Gruij FR. p53 Mutations as a marker of skin cancer risk: comparison of UVA and UVB effects. *Exp Dermatol.* 2002;11(suppl 1):37-39.

16. El-Domyati MB, Attia S, Saleh F, et al. Expression of p53 in normal sun-exposed and protected skin (type IV-V) in different decades of age. *Acta Derm Venereol.* 2003;83:98-104.
17. Wang PL, Sait F, Winter G. The "wildtype" conformation of p53: epitope mapping using hybrid proteins. *Oncogene.* 2001;20:2318-2324.
18. Wikonkal NM, Brash DE. Ultraviolet radiation induced signature mutations in photocarcinogenesis. *J Invest Dermatol Symp Proc.* 1999;4:6-10.
19. Fisher GJ, Choi HC, Bata-Csorgo Z, et al. Ultraviolet irradiation increases matrix metalloproteinase-8 protein in human skin in vivo. *J Invest Dermatol.* 2001;117:219-226.
20. Ichihashi M, Ueda M, Budiyo A, et al. UV-induced skin damage. *Toxicology.* 2003;189:21-39.
21. Brash DE. Sunlight and the onset of skin cancer. *Trends Genet.* 1997;13:410-414.
22. David LM, Lask GP, Glassberg E, Jacoby R, Abergel RP. Laser abrasion for cosmetic and medical treatment of facial actinic damage. *Cutis.* 1989;43:583-587.
23. Coleman W III, Yarborough JM, Mandy SS. Dermabrasion for prophylaxis and treatment of actinic keratoses. *Dermatol Surg.* 1996;22:17-21.
24. El-Domyati MM, Attia SK, Saleh FY, Ahmad HM, Gasparro FP, Uitto JJ. Effect of topical tretinoin, chemical peeling and dermabrasion on p53 expression in facial skin. *Eur J Dermatol.* 2003;13:433-438.
25. Greenblatt MS, Bennett WP, Hollstein M, Harris CC. Mutations in the p53 tumor suppressor gene: clues to cancer etiology and molecular pathogenesis. *Cancer Res.* 1994;54:4855-4878.
26. Berne B, Ponten J, Ponten F. Decreased p53 expression in chronically sun-exposed human skin after topical photoprotection. *Photodermatol Photoimmunol Photomed.* 1998;14(5-6):148-153.
27. Healy E, Reynolds NJ, Smith MM, Campbell C, Farr PM, Rees JL. Dissociation of erythema and p53 protein expression in human skin following UVB irradiation, and induction of p53 protein and mRNA following application of skin irritants. *J Invest Dermatol.* 1994;103:493-499.
28. Perez-Losada J, Balmain A. Stem-cell hierarchy in skin cancer. *Nat Rev Cancer.* 2003;3:434-443.
29. Owens DM, Watt FM. Contribution of stem cells and differentiated cells to epidermal tumours. *Nat Rev Cancer.* 2003;3:444-451.
30. Alonso L, Fuchs E. Stem cells of the skin epithelium. *Proc Natl Acad Sci U S A.* 2003;100(suppl 1):11830-11835.
31. Urato N, Anderson R, Murphy JE, Kupper TS. Replacement of actinically damaged p53 mutant interfollicular epidermal stem cell compartment with normal actinically protected stem cells after CO2 laser resurfacing [abstract]. *J Invest Dermatol.* 2002;119:290.

### News and Notes

#### Dermatology Lexicon Project

Dermatologists have the unprecedented opportunity to apply their expertise to a comprehensive dermatology terminology to improve communication, image indexing, computerized medical records, and research.

Who: Dermatology Lexicon Project

What: Open Comment Period

When: September 1, 2004, through October 31, 2004

Where: [www.dermatologylexicon.org](http://www.dermatologylexicon.org)

How: All it takes is 30 minutes to ensure all skin diseases are included, suggest synonyms, and identify rare and orphan diseases for version 1.0.

For more information e-mail [jennifer\\_byrnes@urmc.rochester.edu](mailto:jennifer_byrnes@urmc.rochester.edu). (This project has been funded in whole or in part with federal funds from the National Institute of Arthritis and Musculoskeletal and Skin Diseases, National Institutes of Health, and Department of Health and Human Services and with funds from The Carl J. Herzog Foundation, Inc, under contract No. NO1-AR-1-2255.)